



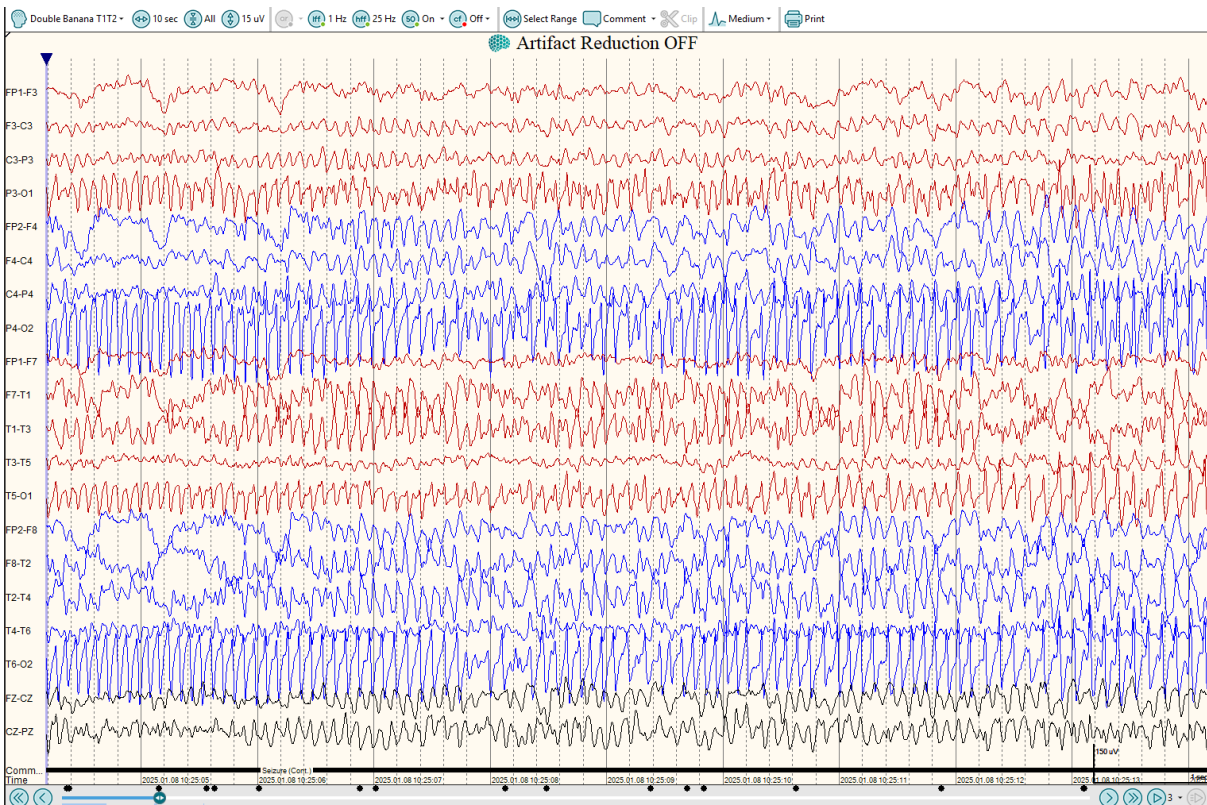
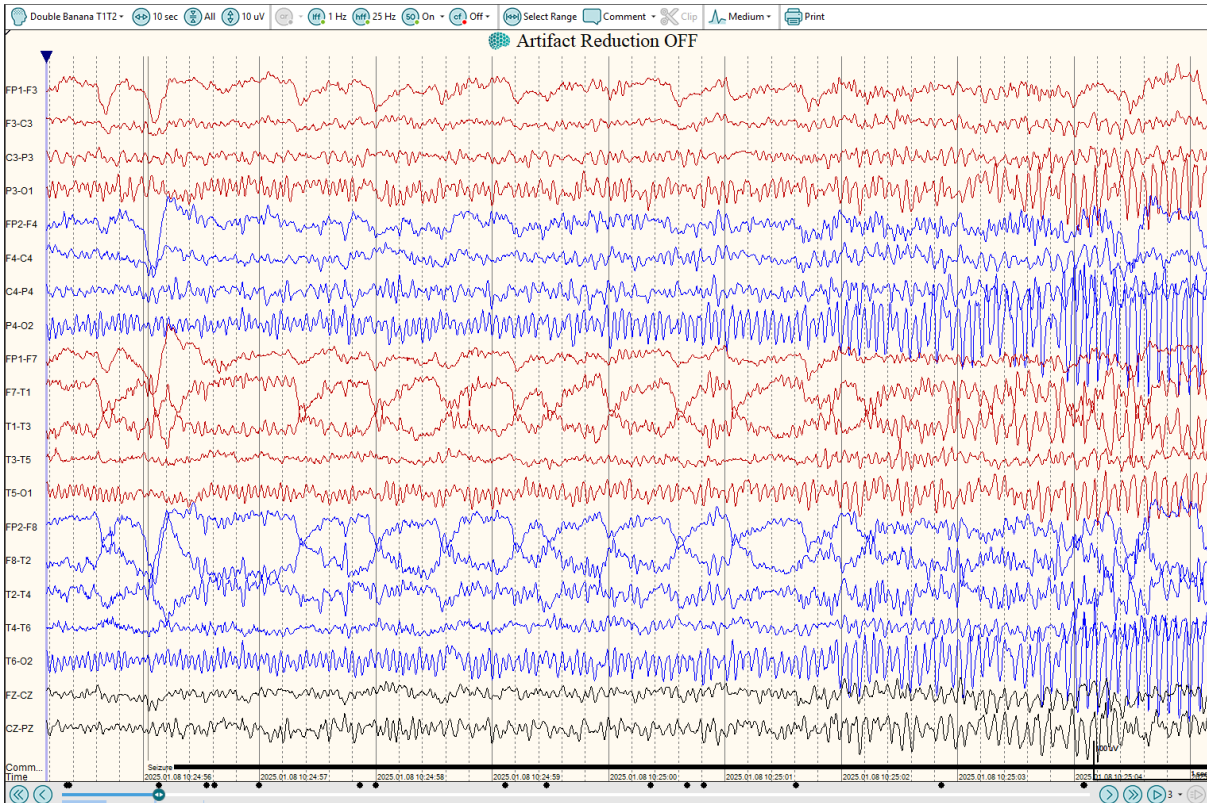
Focal Seizures Arising from the Right Posterior Temporo-Occipital Region in a Pediatric Patient: Evaluation via In-Patient Video-EEG Monitoring

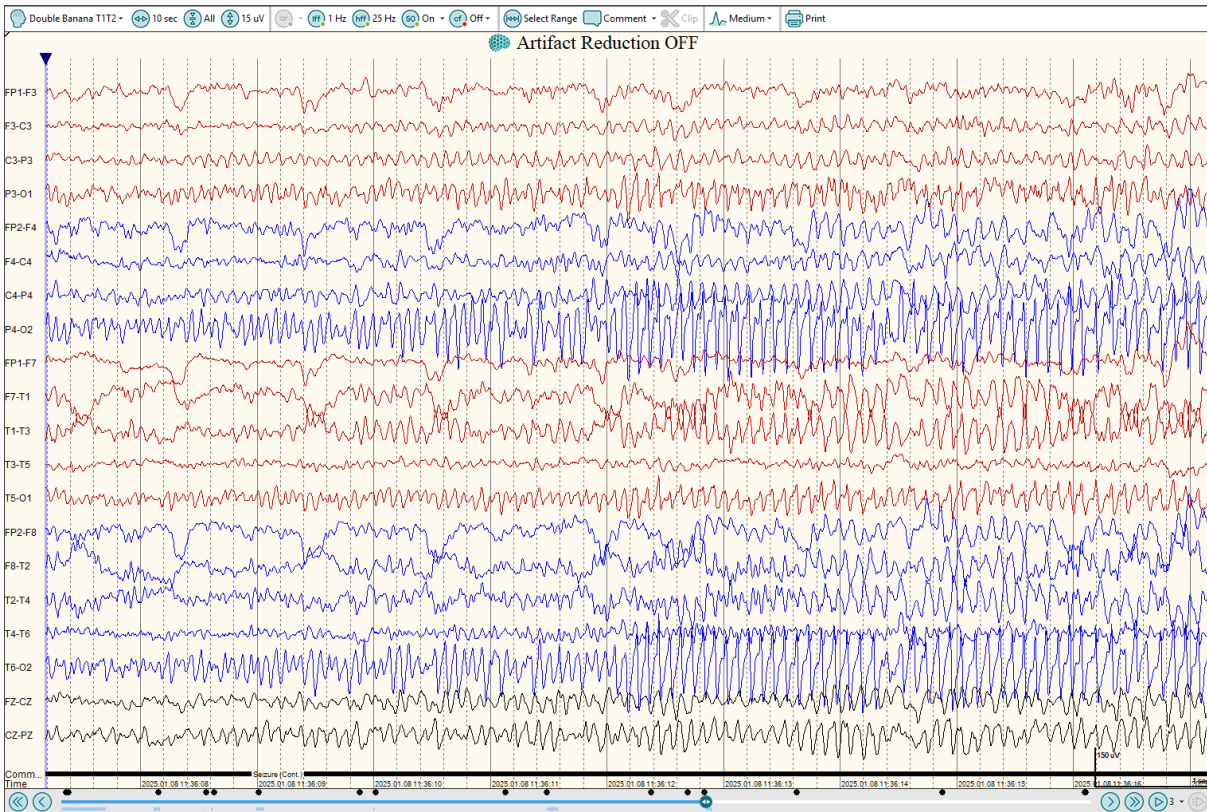
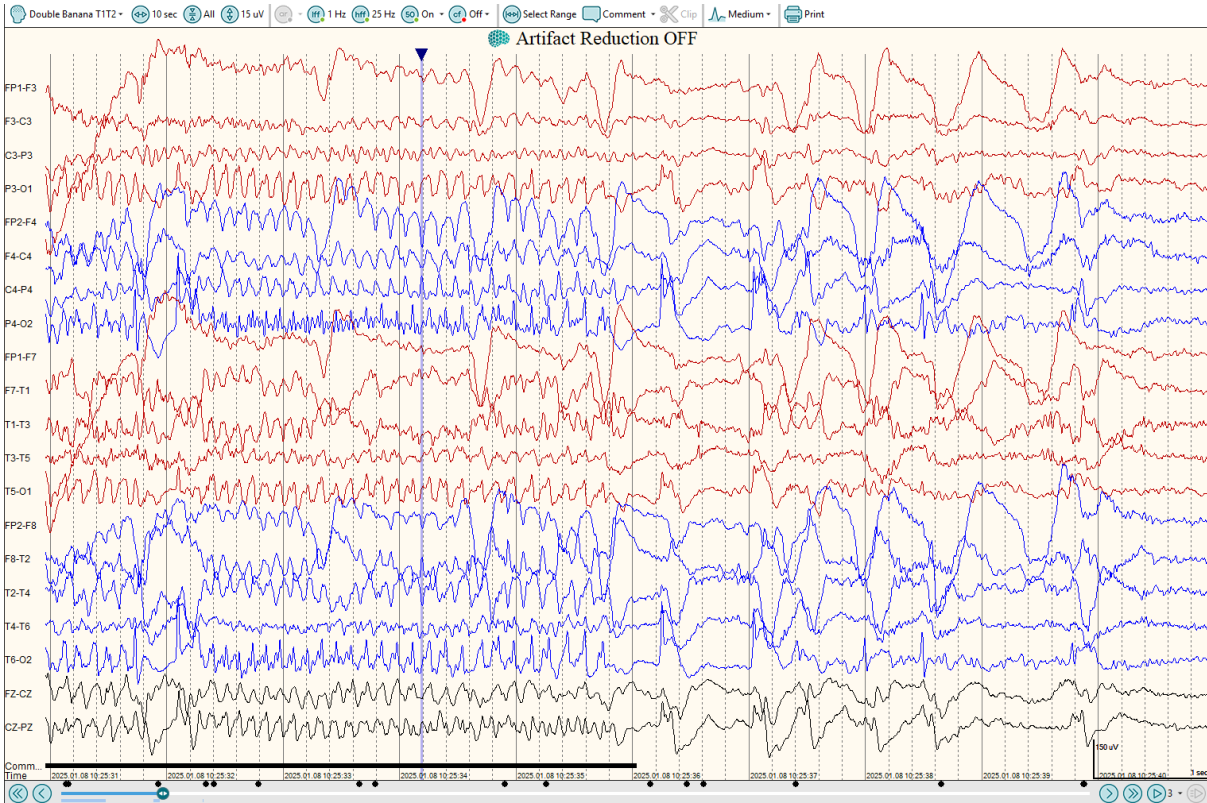Patient History

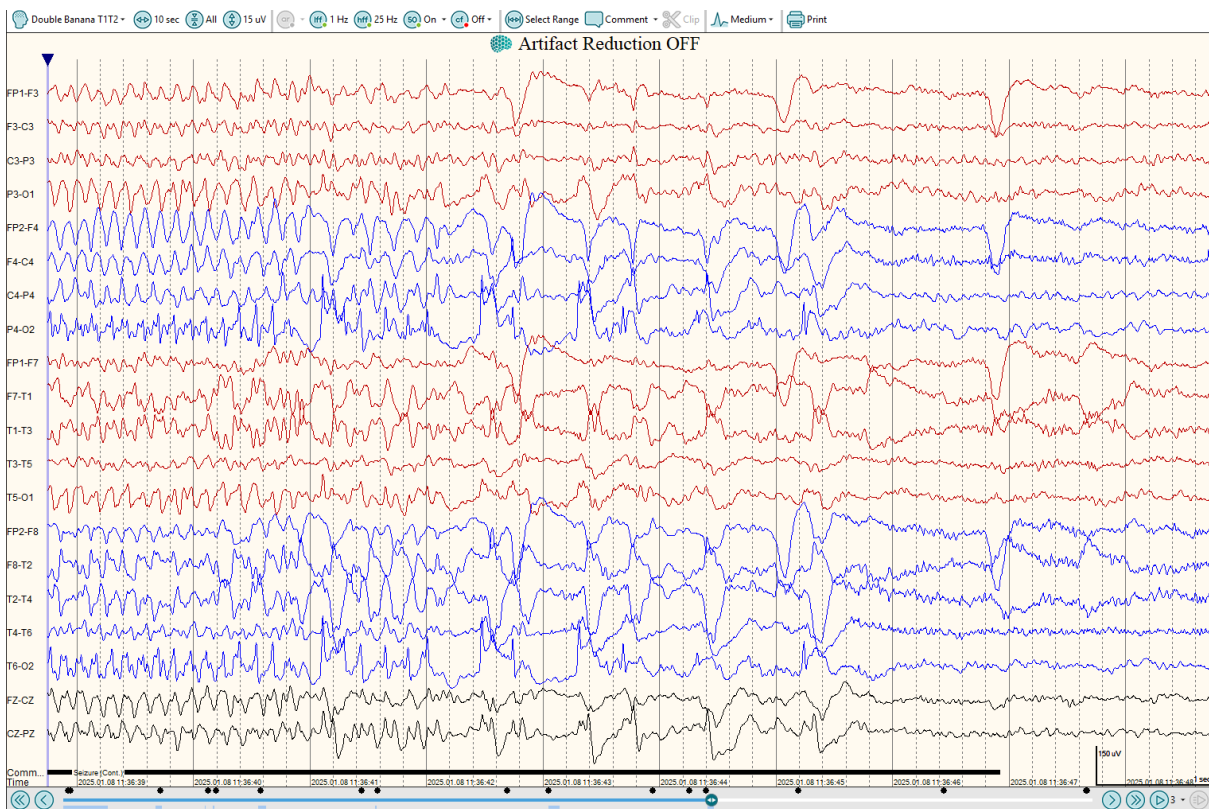
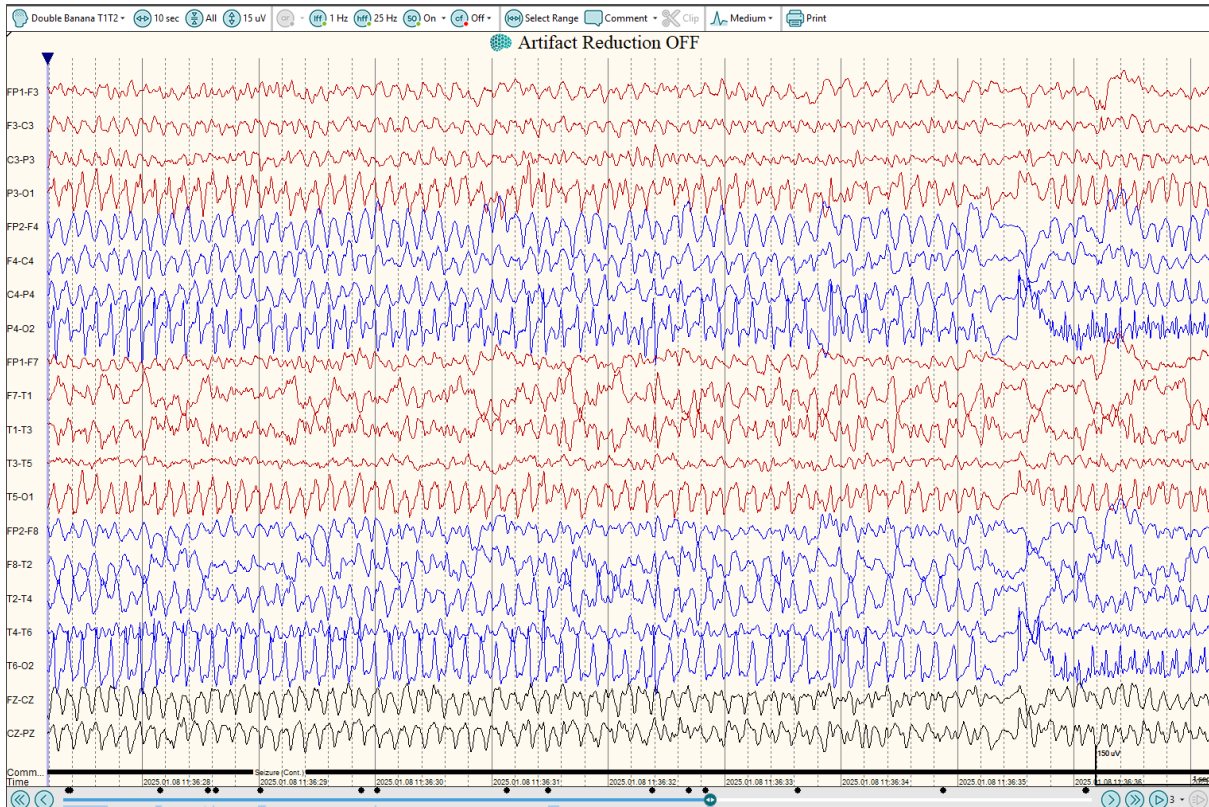
A 10-year-old male child presented with recurrent episodes of sudden rightward deviation of the head and eyes, each lasting approximately 20 seconds, occurring 2–10 times per day. The child was born at full term by LSCS with normal developmental milestones except for a history of speech delay. During the episodes, he remained fully conscious and aware, experienced an aura, and was able to communicate and follow commands, with no associated limb jerking or postictal confusion. Previous EEG demonstrated right hemispheric spike-and-wave discharges. Contrast-enhanced MRI brain revealed frontal white matter changes with non-specific gliosis, with a possibility of a left frontal focal lesion on review. Despite treatment with multiple antiseizure medications including Levetiracetam, Valproate, and Clobazam, the seizures persisted, prompting admission for in-patient video-EEG monitoring. The synchronized video and EEG data obtained using the Mocxa solution enabled a clear understanding of the relationship between the patient's clinical manifestations and their underlying electrophysiological activity.

Procedure Details

Location	In-Patient
Duration	3.3 Hours
EEG Type	Ambulatory, 23 channels, With Video

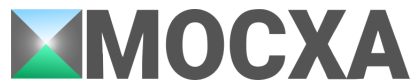





Report

Inter Ictal:- Throughout the record there were no interictal abnormalities seen in this 3.30 hours. Clinical Attacks:- Five clinical episodes observed during short term (3.30



hours) video EEG recording. Ictal Events:- Patient had five ictal events during the video EEG, all five episodes are identical. The patient was fully and conscious and able to follow all the comments during ictus. The patient was able to answer all the questions, count numbers correctly, identify colours correctly, and do the simple calculation. There was no eye movement, facial movement, limb movement during this ictus and the same thing was observed in all five episodes. Ictal EEG:- Ictal EEG is also identical during the events. EEG showed build up of the activity in the form of high voltage sharp wave, spike and spike & wave activity starts from right sided posterior temporo-occipital leads T6-O2, P4-O2. The build up with synchronized activity goes on for five seconds then become secondary generalized spreading to all leads. This generalized activity is of spike and wave lasts for 25-35 seconds and slowly returns to normal with intermittent sharp wave and spike discharges confined to the same posterior parieto-occipital and temporo-occipital leads. Throughout the period the patient was fully alert and had no obvious movements or alteration in sensorium. Impression:- This short term EEG recorded over 3.30 hours had five ictal episodes as mentioned above where the clinical events were unremarkable showing only Ictal EEG abnormality suggestive of seizure arising from right sided posterior temporo-occipital leads. This could suggest the possibility of seizure with impaired consciousness arising from the right sided occipital region.